

# Patient History

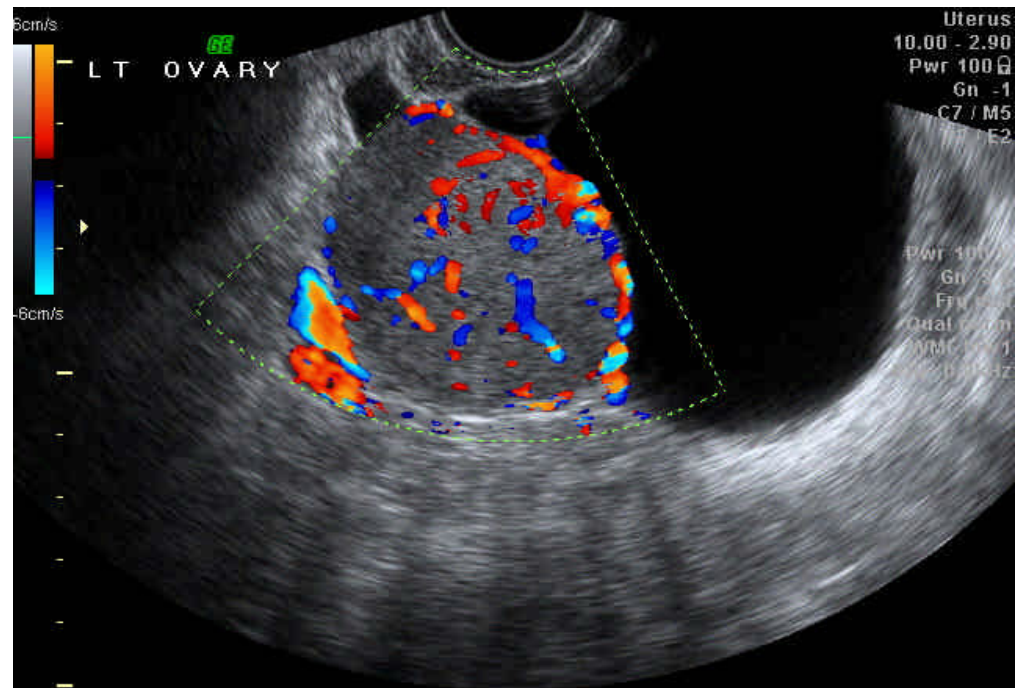
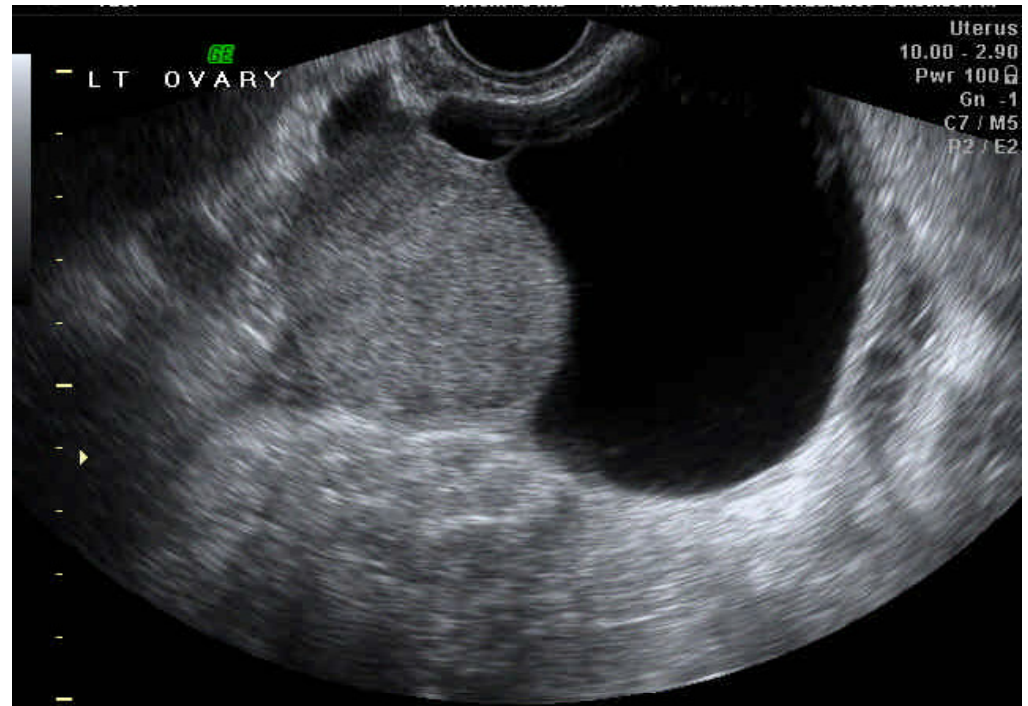
- Patient is a 32 y.o. with history of thyroid cancer.
  - Patient was diagnosed in 1994
  - Had a subtotal thyroidectomy, with partial left lobe remaining and was also treated with I-131 ablation.
  - Had partial left lobe removed 1997. Due to palpable neck mass and positive reoccurrence of thyroid cancer.

# Patient History

- 2010; Patient presented to the Emergency Room with general pelvic pain. A CT scan revealed a pelvic mass in the right adnexa.
- Patient then had an endovaginal ultrasound done in her physicians office.

# What do think this is?

- Based on these findings and history the patient had a right oophorectomy.



# Diagnosis

- Metastatic follicular carcinoma of the thyroid.

# Patient history follow-up

- From initial diagnosis in 1994 until 2010 patient has had 6 reoccurring episodes of metastatic disease.
- Mets are in her lungs, brain, scalp and choroids of her left and right eyes.
- Currently, the patient is under the care of home hospice.